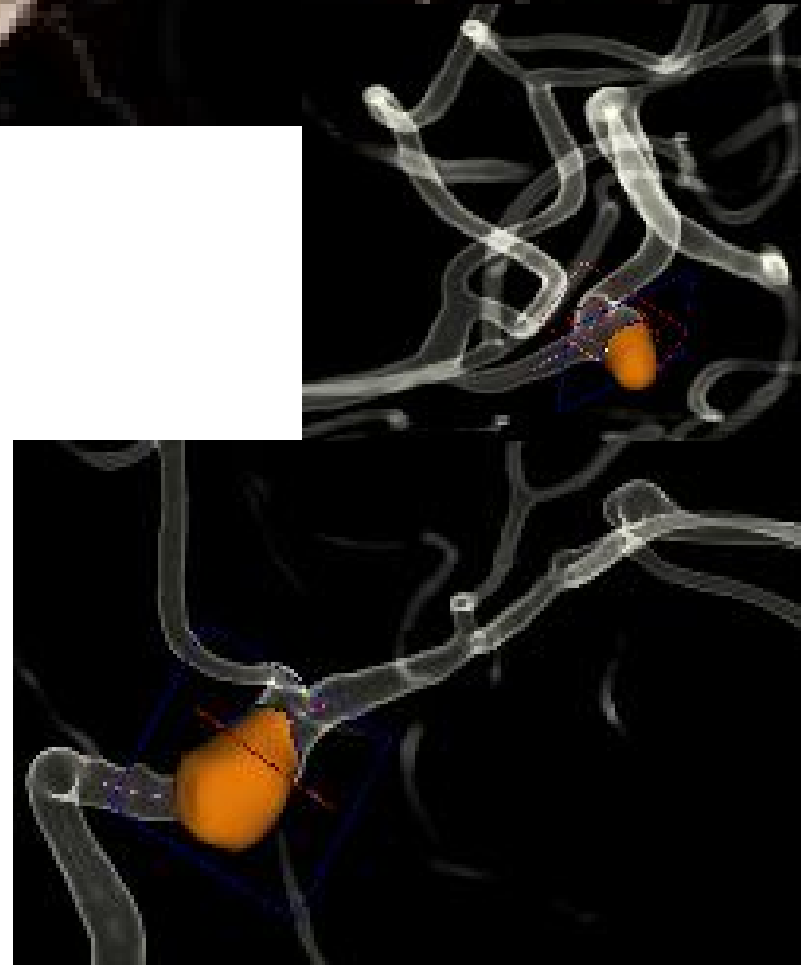
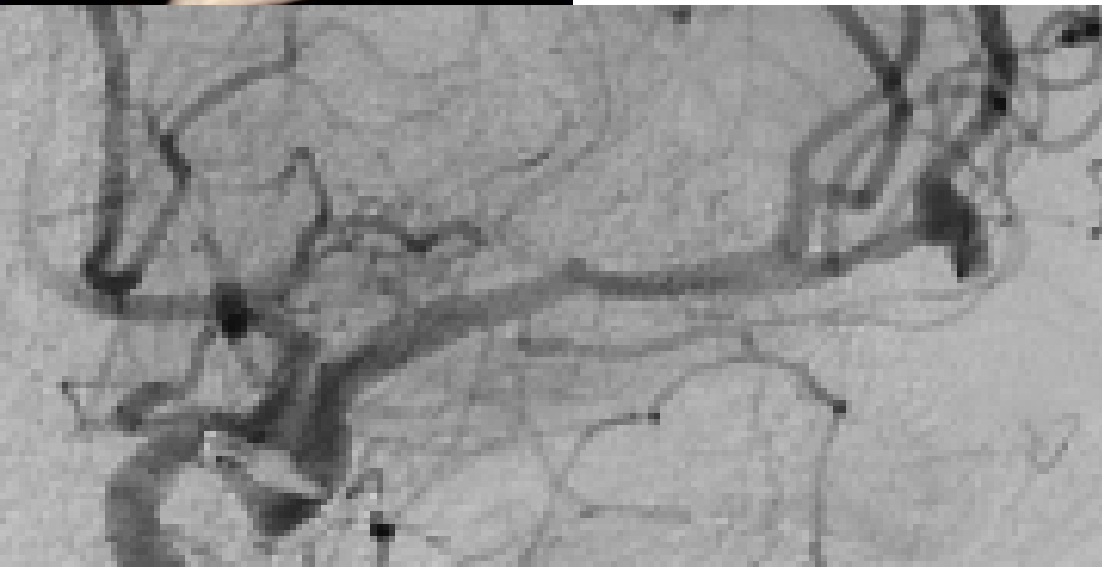
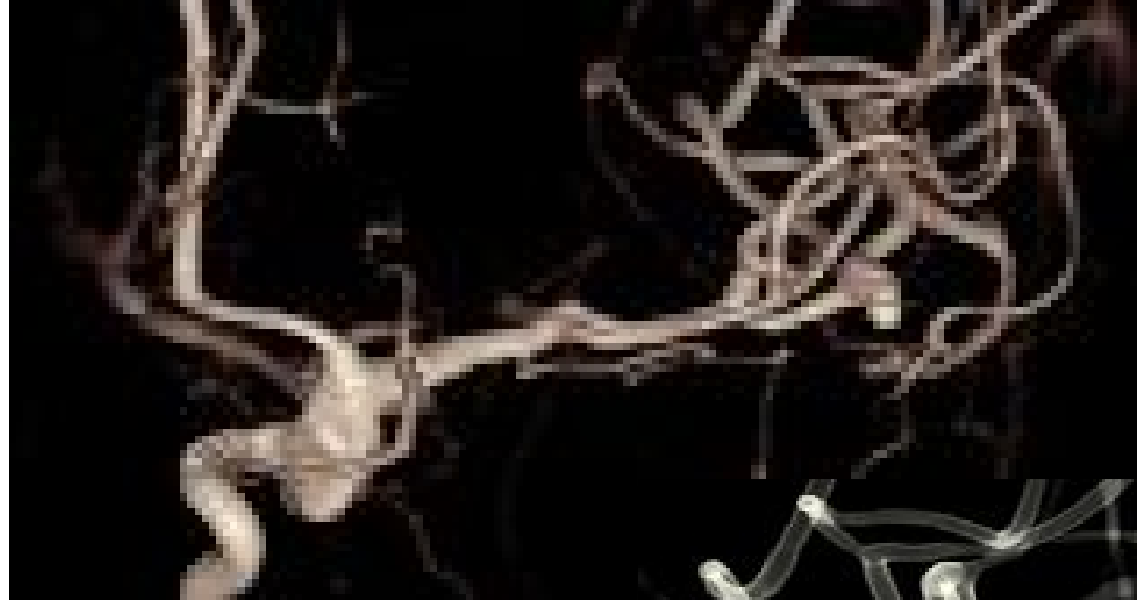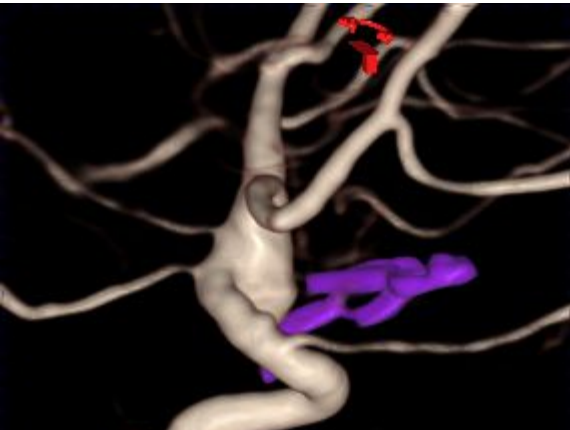


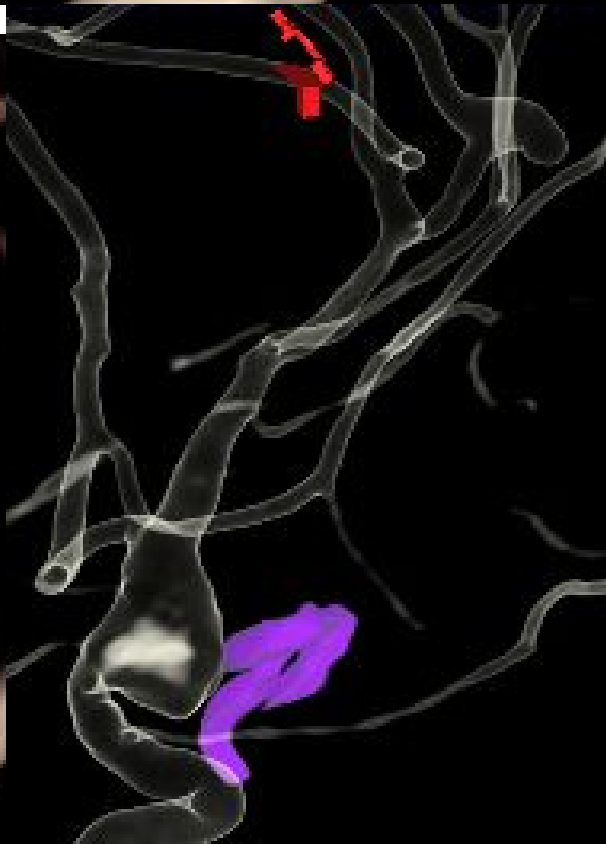
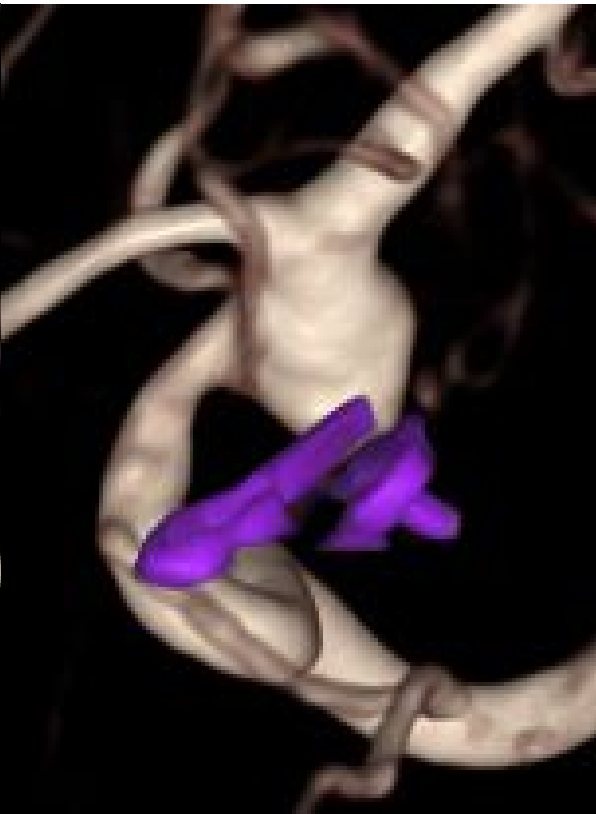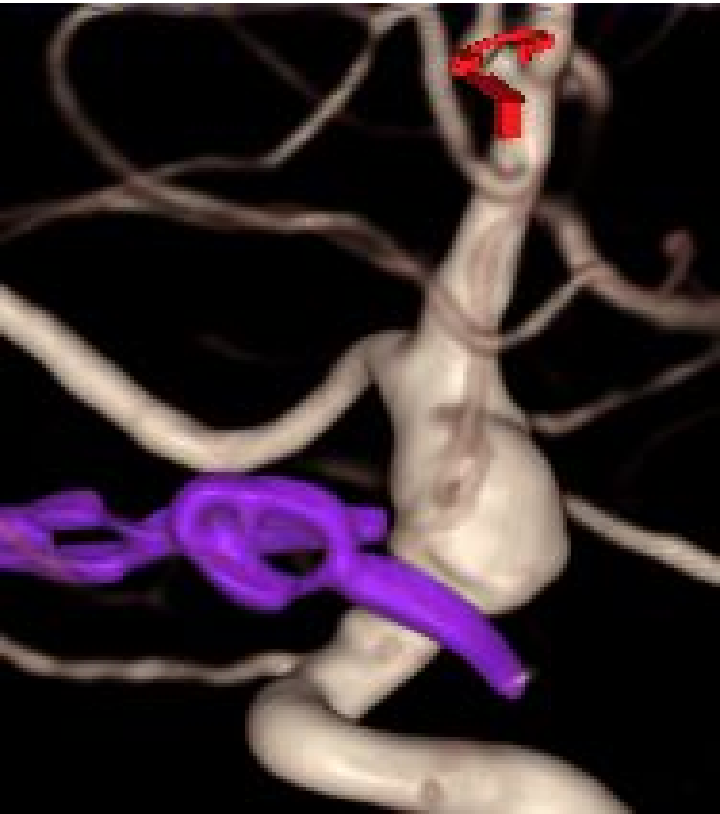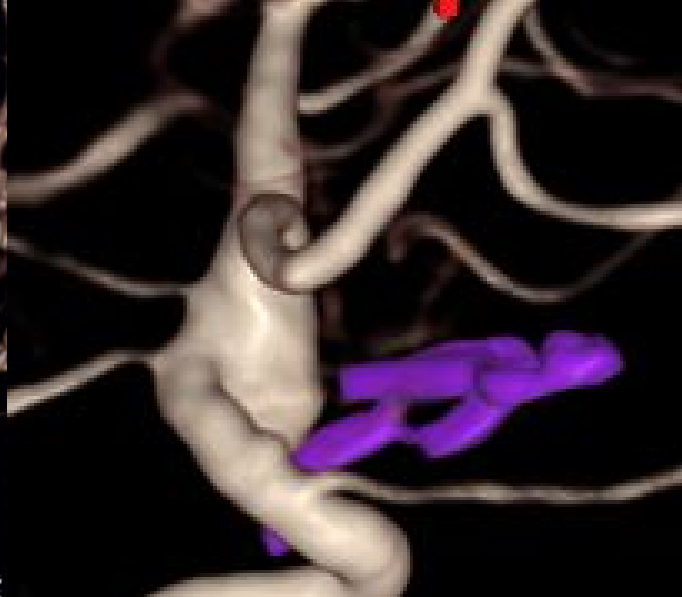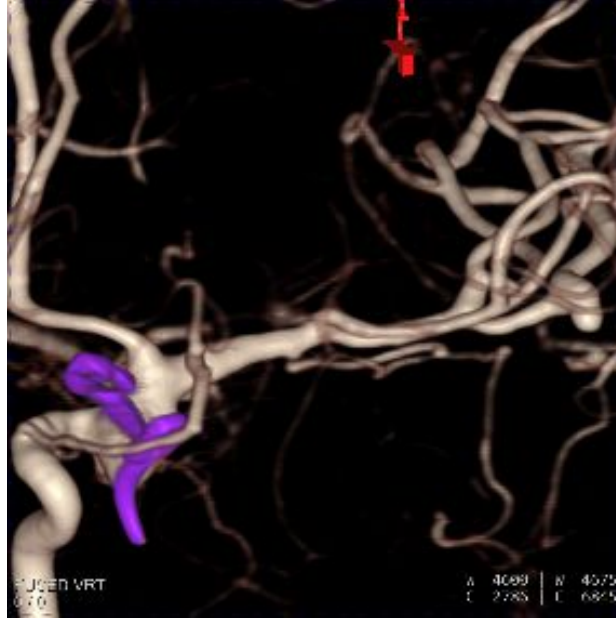
**TRATAMIENTO DE ANEURISMA FUSIFORME DE CAROTIDA SUPRACLINOIDEA (FLOW DIVERTER)
ANEURISMA DE RAMA M2 DE LA ACM (STENT-COILS).**

ANEURISMA DE ACI INTERVENIDO HACE 20 AÑOS.

ANEURISMA DE RAMA M2 EN LA ZONA DE UNION DE BY PASS

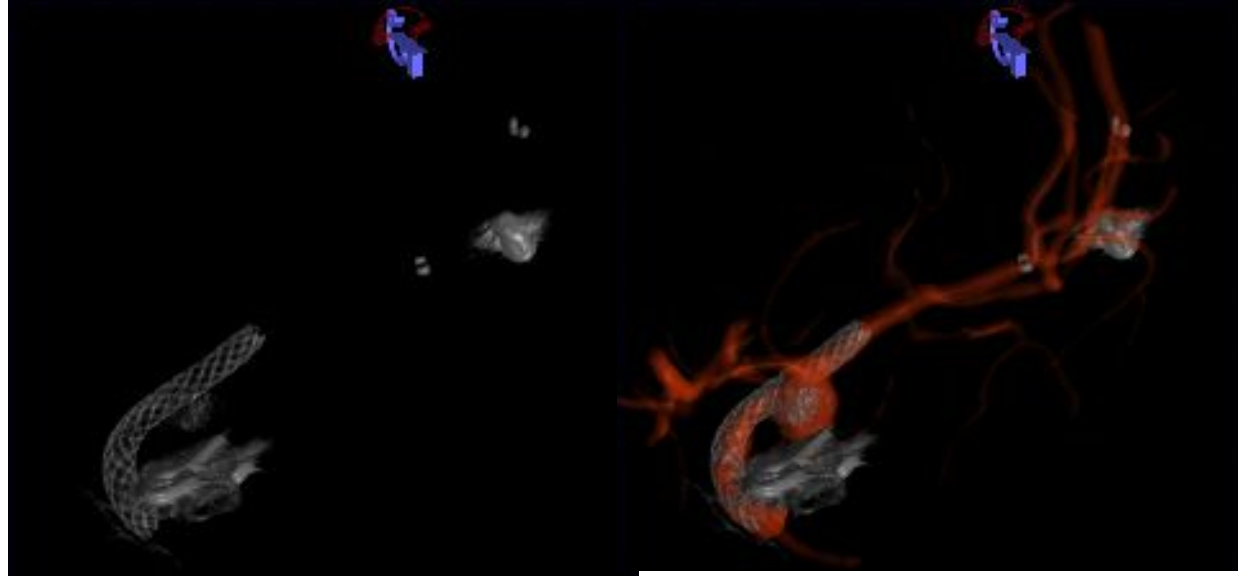


**TRATAMIENTO DE ANEURISMA
FUSIFORME DE CAROTIDA
SUPRACLINOIDEA (FLOW
DIVERTER)
ANEURISMA DE RAMA M2 DE LA
ACM (STENT-COILS)**



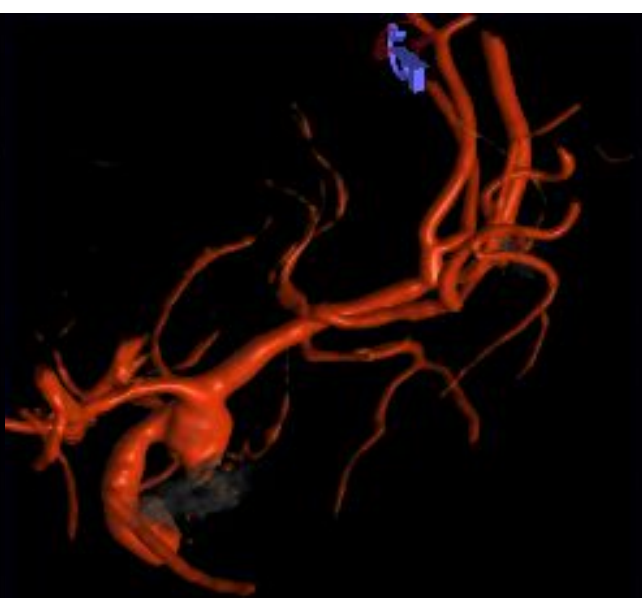
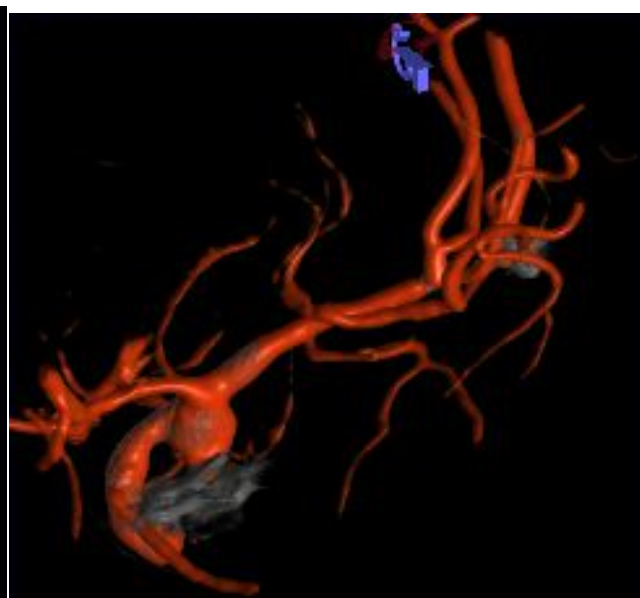
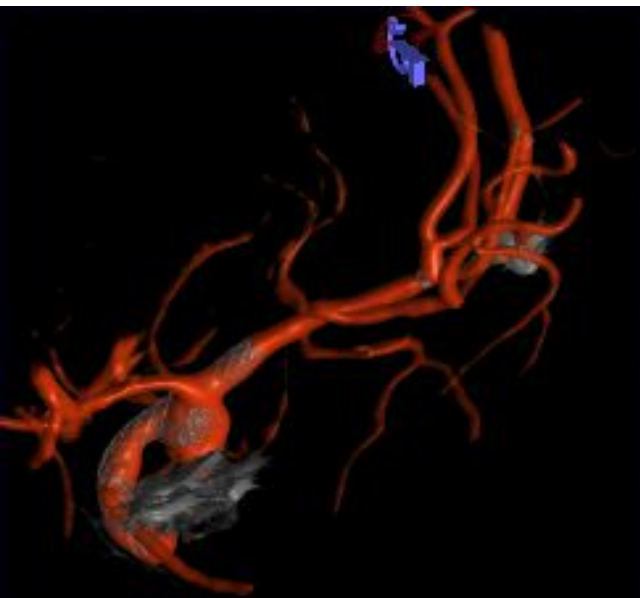
**TRATAMIENTO DE ANEURISMA
FUSIFORME DE CAROTIDA
SUPRACLINOIDEA (FLOW
DIVERTER)**

**ANEURISMA DE RAMA M2 DE LA
ACM (STENT-COILS)**



**STENT FLOW DIVERTER SURPASS 3X
20 MM.**

STENT ATLAS –COILS GDC



**TRATAMIENTO DE ANEURISMA
FUSIFORME DE CAROTIDA
SUPRACLINOIDEA (FLOWAW
DIVERTER)
ANEURISMA DE RAMA M2 DE
LA ACM (STENT-COILS)**

